

## Role of Signal Processing in Eye Care

### A collaboration between the Department of Ophthalmology<sup>1</sup> and the Biomedical Engineering Group<sup>2</sup>

Mark Alberti, MD<sup>1</sup>

Sadasivan Puthusserypady, M.Tech, PhD, Assoc. Prof.<sup>2</sup>

Ulrik Christensen, MD, PhD, Assoc. Prof.<sup>1</sup>

Javier Cabrerizo, MD, PhD<sup>1</sup>

Morten la Cour, MD, DMSc, Prof.<sup>1</sup>

The treatment of several eye diseases requires proper patient management before, during and after surgery to prevent vision loss. For surgically treated eye diseases this means providing ideal physical and biomechanical conditions for the afflicted eye. To this aim patient positioning is prescribed in the treatment of corneal diseases in the front of the eye to retinal diseases in the back of the eye (see figure 1)<sup>1,2</sup>. Visual loss or failed surgery is often attributed to poor adherence to recommended positioning (poor compliance) as positioning regimens are challenging<sup>3</sup>. In the following eye conditions, patient positioning plays a major role in the treatment regimen:

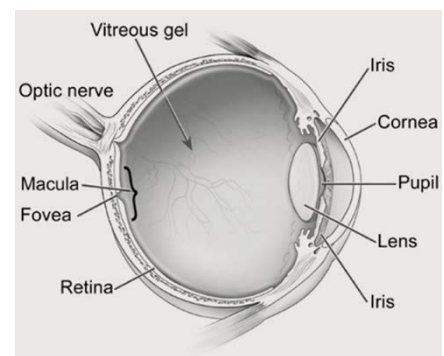


Figure 1. Anatomy of the human eye (cross section).

- **Macular hole** – an eye disease with a small break in the center of the eye's light-sensitive retina. It results in distorted and decreased central vision preventing reading, driving, and seeing fine detail, but can be treated by surgery (vitrectomy) and filling the eye with gas. Appropriate positioning for 3 days postoperatively ensures contact between the retina and the gas bubble necessary for hole closure and visual improvement<sup>4</sup>.
- **Fuchs' endothelial dystrophy** - a condition causing blurred vision. An accumulation of focal outgrowths and thickening of inner corneal membrane (Descemet's membrane) leads to corneal swelling and vision loss. Treated surgically with a partial-thickness cornea transplant procedure (Descemet membrane endothelial keratoplasty, DMEK). Postoperatively a gas bubble ensures fusion of the donor membrane and the recipient cornea facilitated by supine positioning for 3-5 days<sup>2</sup>.

<sup>1</sup> Rigshospitalet – Glostrup, Denmark

<sup>2</sup> Technical University of Denmark

- **Retinal detachment** - disorder of the eye where the light-sensitive retina separates from the cell layer lining the wall of the eye. It often involves permanent vision loss in the affected area. Positioning is prescribed preoperatively (0-72 hours) to prevent further detachment of the retina and worsening of vision loss<sup>5</sup>.

The purpose of this research is to improve patient's vision in the treatment of macular holes and Fuchs' corneal endothelial dystrophy and to prevent progression of retinal detachment through biomechanical knowledge of these conditions.

At the Department of Ophthalmology, Rigshospitalet – Glostrup we have studied the relationship between the actual performed positioning and surgical results in macular hole treatment (unpublished data, submitted for publication). Recently we have adopted DMEK for the treatment of Fuchs' endothelial dystrophy. In both DMEK and macular hole treatments similar key principals are at play. They utilize the physical properties of gas with a high surface tension and low viscosity to create a biomechanical environment enabling visual gain<sup>6</sup>. As positioning determines the location of the gas in the eye (through gravity), it directs the therapeutic effect of the gas bubble. In patients with a retinal detachment we have also studied the effects of positioning by assessing the retinal detachment progression rate in admitted patients<sup>5</sup>. Here, the vulnerable detached retina is subject to the effects of gravity, head motion and eye movements. Forces acting on the detached retina are thought to promote the progression of detachment. However, very little is known about forces and stresses in the eye before and after surgery. Knowledge and data on the role of the mechanics affecting the eye would likely allow us to improve patient care.

Objective recording is crucial for our understanding of the effects of gravity on gas in the eye. As there is often a large discrepancy between the positioning prescribed by surgeons and the actual positioning performed by patients it is not enough merely to rely on the surgeon prescribed positioning. At the Department of Ophthalmology, Rigshospitalet – Glostrup we have developed a novel device for monitoring the patient's head position with small, low-power electronic sensors (accelerometer and gyroscope). With this 'positioning device' we have demonstrated a benefit of gas-macular-hole contact for achieving hole closure (see figure 2) and have eliminated a previously standard unnecessarily arduous positioning regimen (face-down position)<sup>7</sup>. Furthermore, we have identified how to improve gas-macular hole contact which we wish to implement to improve the macular hole treatment regimen.

A significant limitation to the 'positioning device' is that it uses head pitch as a proxy to estimate eye position. Without knowledge of the eye position in relation to the head we are unable to precisely determine the location of the gas bubble postoperatively or determine whether head or eye

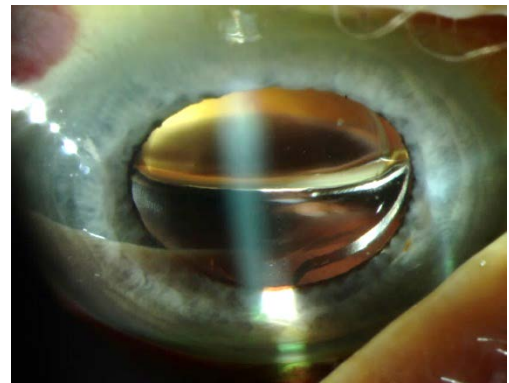
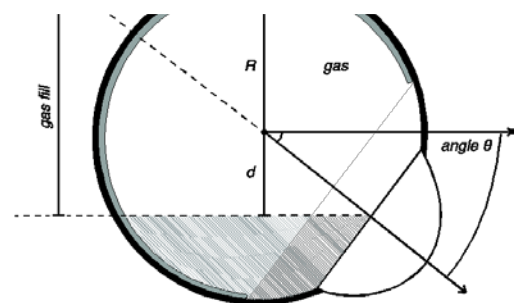


Figure 2A. Above: Image of gas in the eye postoperatively with a gas-fluid meniscus seen in the middle of the pupil.

Figure 2B. Below: Figure of an eye with a large gas bubble. The macular area is in contact with gas, however, with upward gaze fluid (gray shading) is in contact with the macula.



movement causes progression in a retinal detachment. The Technical University of Denmark collaboration provides a solution to this problem with electrooculography (EOG). EOG is a technique for measuring the corneo-retinal standing potential that exists between the front and the back of the human eye. The resulting signal (electrooculogram) allows for the recording of eye movements<sup>8</sup>. Long-term gaze recording is possible even at night with the eyes closed. It is, however, a difficult task analyzing the raw recordings and requires engineering expertise to remove artifacts from blinking, separate the EOG signal from drift and control for the variable corneo-retinal potential.

Fusing EOG with an updated positioning device represents a novel approach to gaining insights to treatments provided to patients. Although the use of positioning is routine, it is without a firm evidence base. By solidifying our understanding of the implications of poor adherence to positioning recommendations and ocular movements we believe we can give better patient care through better guidance and devices that actively assist patients to position better. Thus, the insights gained from looking at clinical outcomes as well as objective measurements will likely allow us to introduce improved treatment regimens that prevent unnecessary vision loss and enhance visual gain.

## Research questions

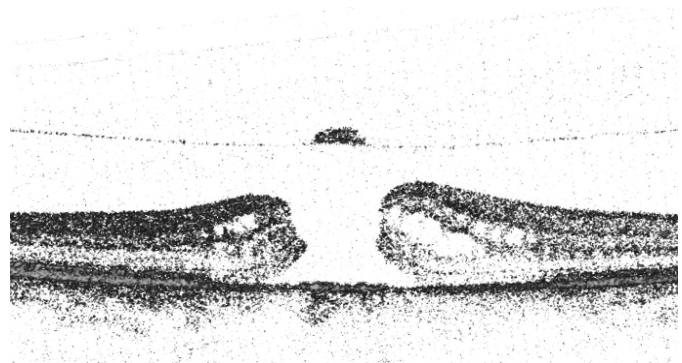
- (1) Can we improve macular hole treatment by assisting patients to better positioning?
- (2) Does better gas-cornea transplant (graft) contact increase the surgical success rate in DMEK?
- (3) What is the relative importance of positioning and eye movement prior to surgery for the progression of a retinal detachment?

## Specific projects

### Macular hole

We plan to build on previous research demonstrating that improved gas-macular hole contact is crucial for hole closure (and therefore also visual improvement). By assisting patient to position better we believe that we can improve the intraocular gas-bubble location to increase the likelihood of hole closure. Particularly at night where the unconscious state hinders compliance we need to assist patients to position better. With macular hole patients randomized to either no positioning or positioning assistance (both ‘passive’ sleep apnea back pillow assistance and ‘active’ positioning device providing tactile feedback)

we seek to determine to what extent we can improve positioning. EOG will allow us to determine a much more precise gas-macular hole contact than previously possible. From measurements of head position and eye position, we can extract the relative importance for maintaining gas-macular hole contact. By supporting patients to better compliance, we seek to reduce the risk of failed surgery and reduce the number of unnecessary re-operations.



*Figure 3. Image of the retina (cross section) with a macular hole.*

### Fuchs' endothelial dystrophy

Descemet membrane endothelial keratoplasty (DMEK) represents the latest refinement of the treatment of endothelial dysfunctions, such as Fuchs' endothelial dystrophy, with better visual outcomes and lower rates of postoperative complications<sup>9</sup>. The recipient Descemet membrane is replaced by a 20-micron thick donor Descemet layer. This enables lower rejection rates, and better visual outcomes mainly due to the lack of an evident donor-recipient interface. Although DMEK is currently considered the premium surgical treatment for endothelial dysfunctions, challenges remain as a high re-operation rate hinders the full benefit and potential of this surgical approach. After placement, the thin donor Descemet's membrane is vulnerable to the shear stress caused by fluid movement in the eye<sup>10</sup>. We believe that it is essential to have gas in contact with the graft postoperatively, as gas with its low viscosity and high surface tension creates the ideal environment for fusion of the donor membrane and the recipient cornea. We seek with this study to determine the role of gas-transplant contact in the postoperative period. With EOG we can determine the relative importance of positioning and eye movements for surgical success. Rapid eye movements in situations where the graft is unsupported by gas is likely devastating to successful surgery. Understanding these relationships will later allow us to modify the treatment regimen to lower re-operation rates.

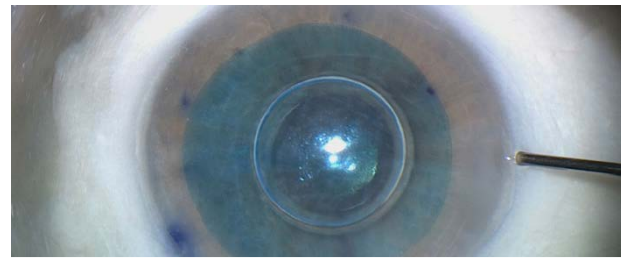


Figure 4. Image of a gas bubble supporting a corneal transplant (stained blue). The photo is taken during surgery with a surgical instrument seen to the right.

### Retinal detachment

The risk of poor visual outcome after rhegmatogenous retinal detachment is highly dependent on the status of the central retina (fovea) prior to surgery<sup>11</sup>. If the retinal detachment progresses to include the fovea, the likelihood of a good visual outcome is reduced. It has also been shown that retinal detachment repair has a better outcome if it is conducted in a specialist retinal unit and better results are achieved when surgery is performed in a routine setting during the daytime (as opposed to nighttime and weekends)<sup>12, 13</sup>. During the delay to surgery relevant preoperative care of patients with a retinal detachment is crucial. Currently the causative factors of progression are unknown, although the duration of surgical delay has been found as a significant risk factor. The goals of this study are twofold, 1) to determine the relative role of eye and head movements (determined by coupling of EOG and positioning device) for progression of a retinal detachment and 2) to discern whether there is benefit of admitting patients to bedrest. Admitting patients is expensive, so if patients can be treated safely in an outpatient setting this would drastically reduce the cost of treatment and allow for resources to be spent better. Zealand, Denmark is an ideal location for this study with one retinal center admitting patients (Rigshospitalet – Glostrup) and one center treating patients in an outpatient setting (Næstved Hospital).

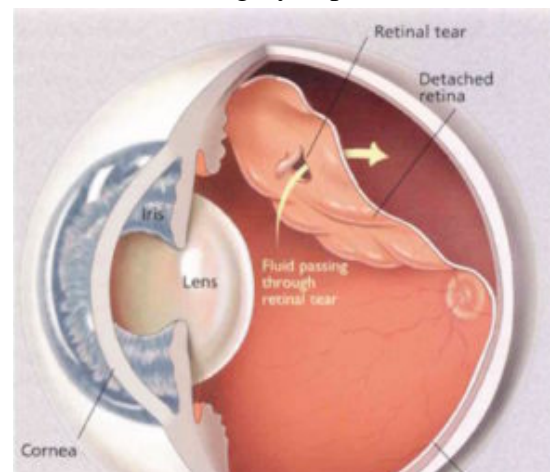


Figure 5. Illustration of a retinal detachment – a medical emergency requiring surgical treatment. The goal of treatment is to reattach the retina to the wall of the eye.

## References

1. Kelly NE and Wendel RT. Vitreous surgery for idiopathic macular holes. Results of a pilot study. *Archives of ophthalmology* 1991; 109:654-659.
2. Dirisamer M et al. Prevention and management of graft detachment in descemet membrane endothelial keratoplasty. *Archives of ophthalmology* 2012; 130:280-291.
3. Verma D et al. Evaluation of posturing in macular hole surgery. *Eye* 2002; 16:701-704.
4. Madi HA, Masri I and Steel DH. Optimal management of idiopathic macular holes. *Clin Ophthalmol* 2016; 10:97-116.
5. Hajari JN et al. Progression of foveola-on rhegmatogenous retinal detachment. *The British journal of ophthalmology* 2014; 98:1534-1538.
6. de Juan E, Jr., McCuen B and Tiedeman J. Intraocular tamponade and surface tension. *Surv Ophthalmol* 1985; 30:47-51.
7. Alberti M and la Cour M. NONSUPINE POSITIONING IN MACULAR HOLE SURGERY: A Noninferiority Randomized Clinical Trial. *Retina* 2016; 36:2072-2079.
8. Stevenson C, Tzyy-Ping J and Cauwenberghs G. Estimating direction and depth of visual fixation using electrooculography. *Conference proceedings : Annual International Conference of the IEEE Engineering in Medicine and Biology Society IEEE Engineering in Medicine and Biology Society Annual Conference* 2015; 2015:841-844.
9. Rodríguez-Calvo-de-Mora M et al. Clinical outcome of 500 consecutive cases undergoing Descemet's membrane endothelial keratoplasty. *Ophthalmology* 2015; 122:464-470.
10. Modarrezadeh S et al. Physiology of aqueous humor dynamic in the anterior chamber due to rapid eye movement. *Physiol Behav* 2014; 135:112-118.
11. Abouzeid H and Wolfensberger TJ. Macular recovery after retinal detachment. *Acta ophthalmologica Scandinavica* 2006; 84:597-605.
12. Comer MB et al. Who should manage primary retinal detachments? *Eye* 2000; 14 ( Pt 4):572-578.
13. Koch KR et al. Success rates of retinal detachment surgery: routine versus emergency setting. *Graefes Arch Clin Exp Ophthalmol* 2012; 250:1731-1736.